

Asportazione manuale in pazienti con Degenerazione Nodulare di Salzmann (SND) atipica

XLIX Congresso Regionale SOSi, 10-12 Aprile 2025, Giardini Naxos

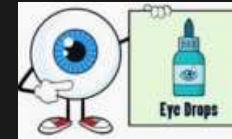
A. Scolaro, C. Azzaro, A. Salsa, A.M. Roszkowska, P. Aragona

SND Management

1. Therapy directed at the underlying cause (if known)

2. Medical therapy (for discomfort):

- Eye lubricants
- Warm compresses
- Eyelid hygiene
- Steroids, NSAIDs, immunomodulators



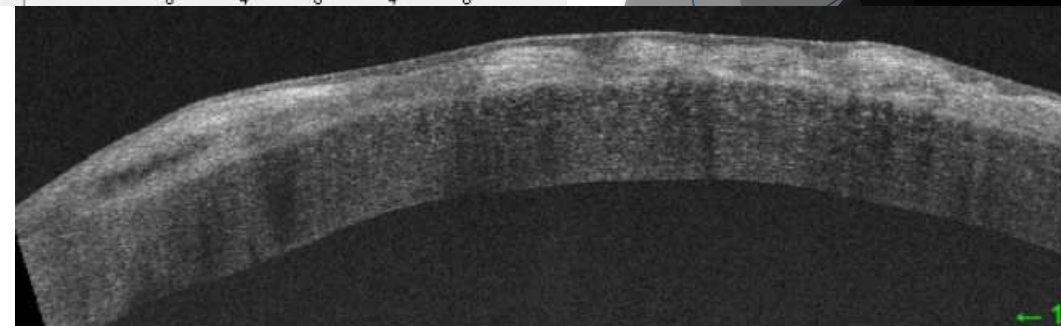
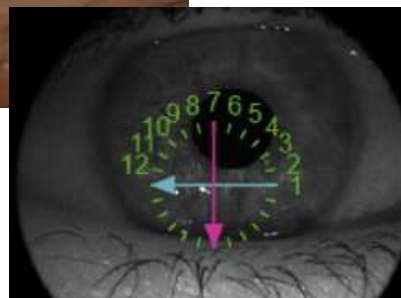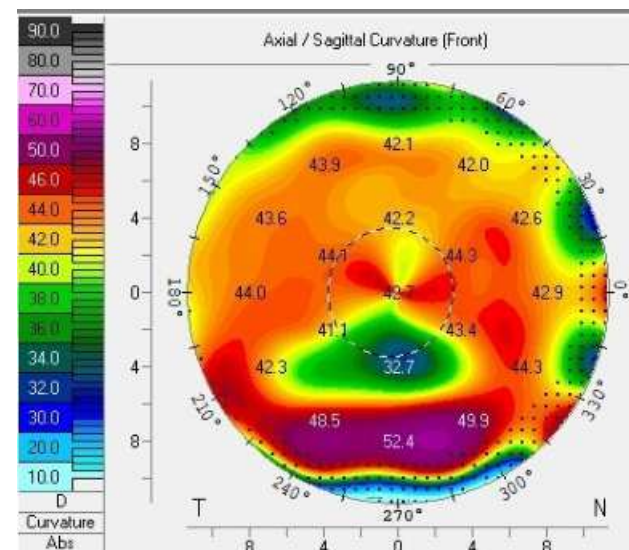
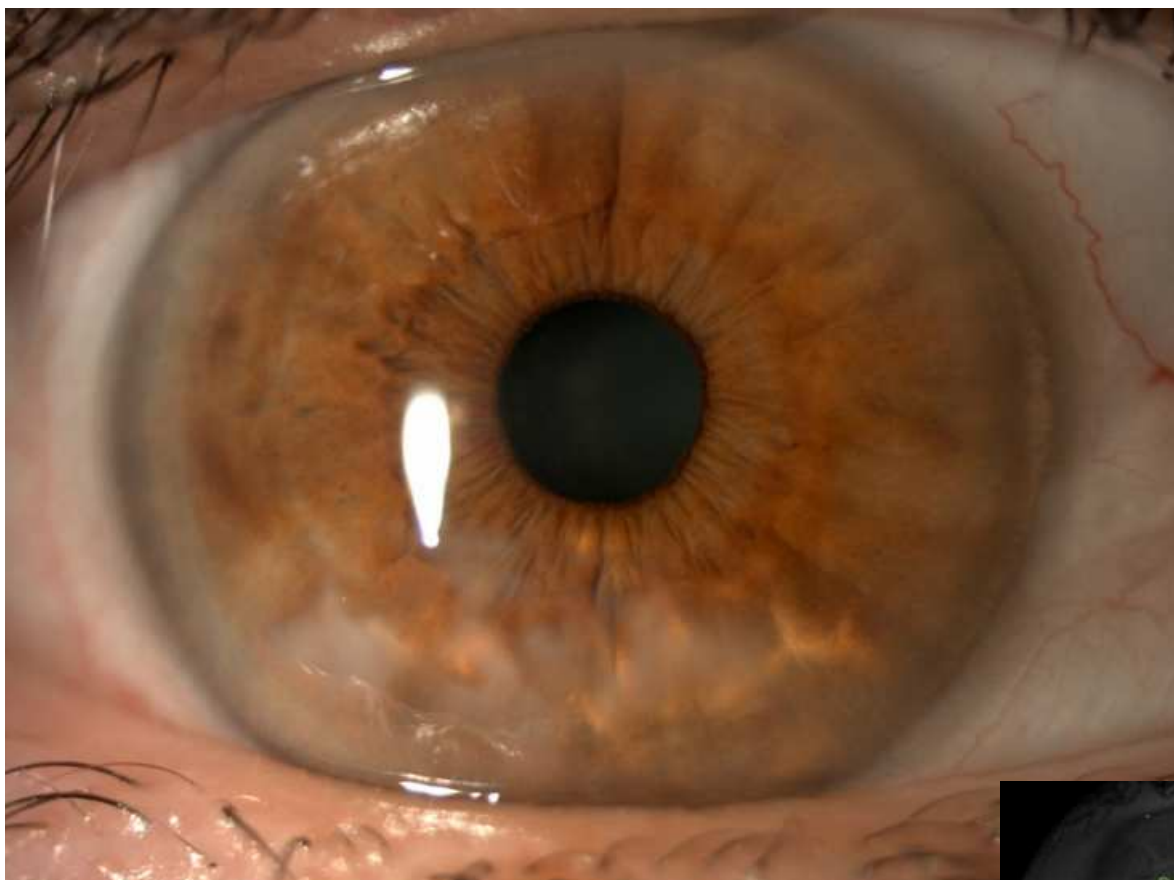
3. Surgery (failure of medical therapy, VA reduction due to irregular astigmatism or nodules near the optical zone)

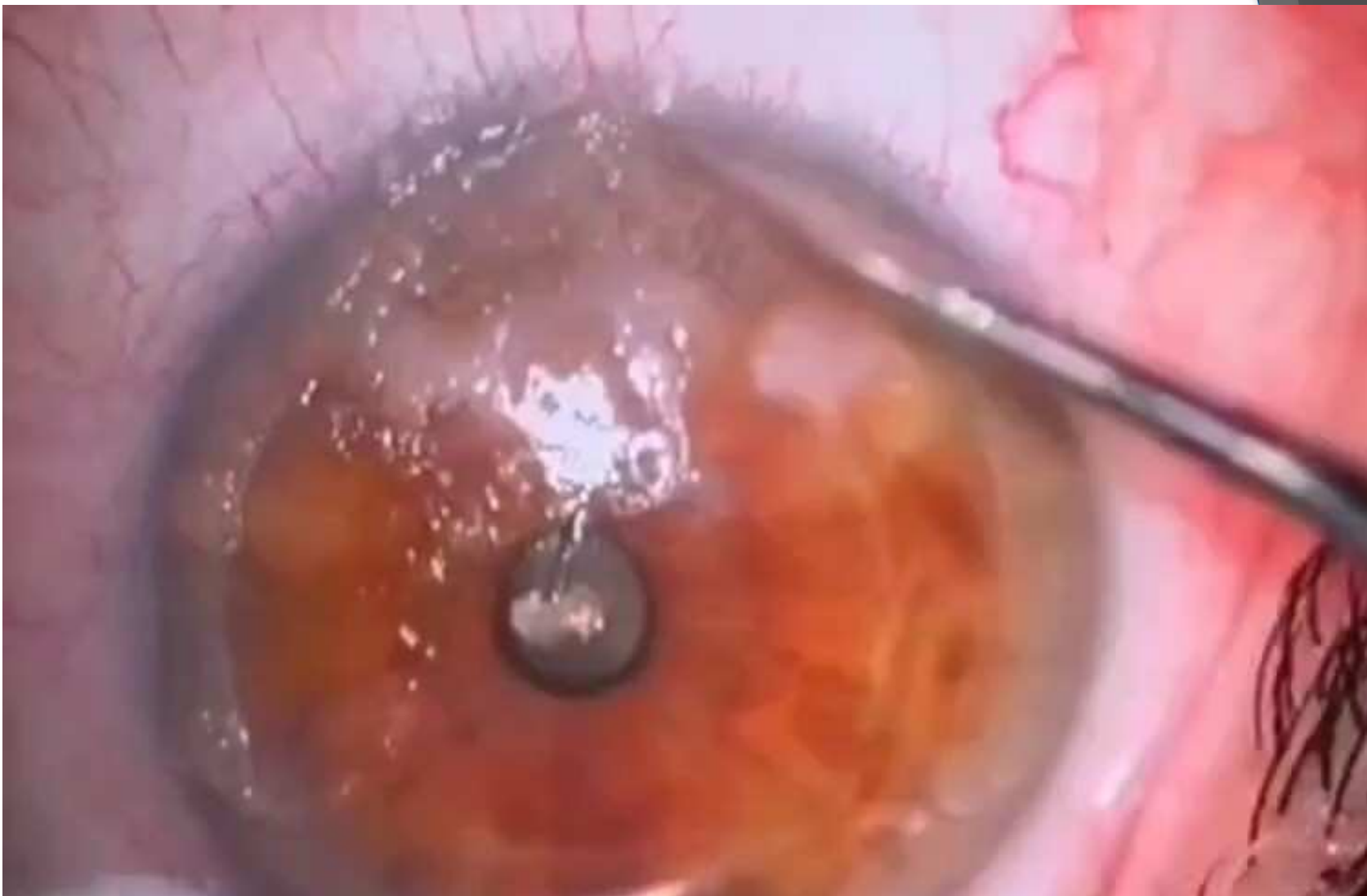
- Manual removal (eventually followed by PTK)
- Superficial keratectomy
- DALK (rare cases)

OCT

CASE 1

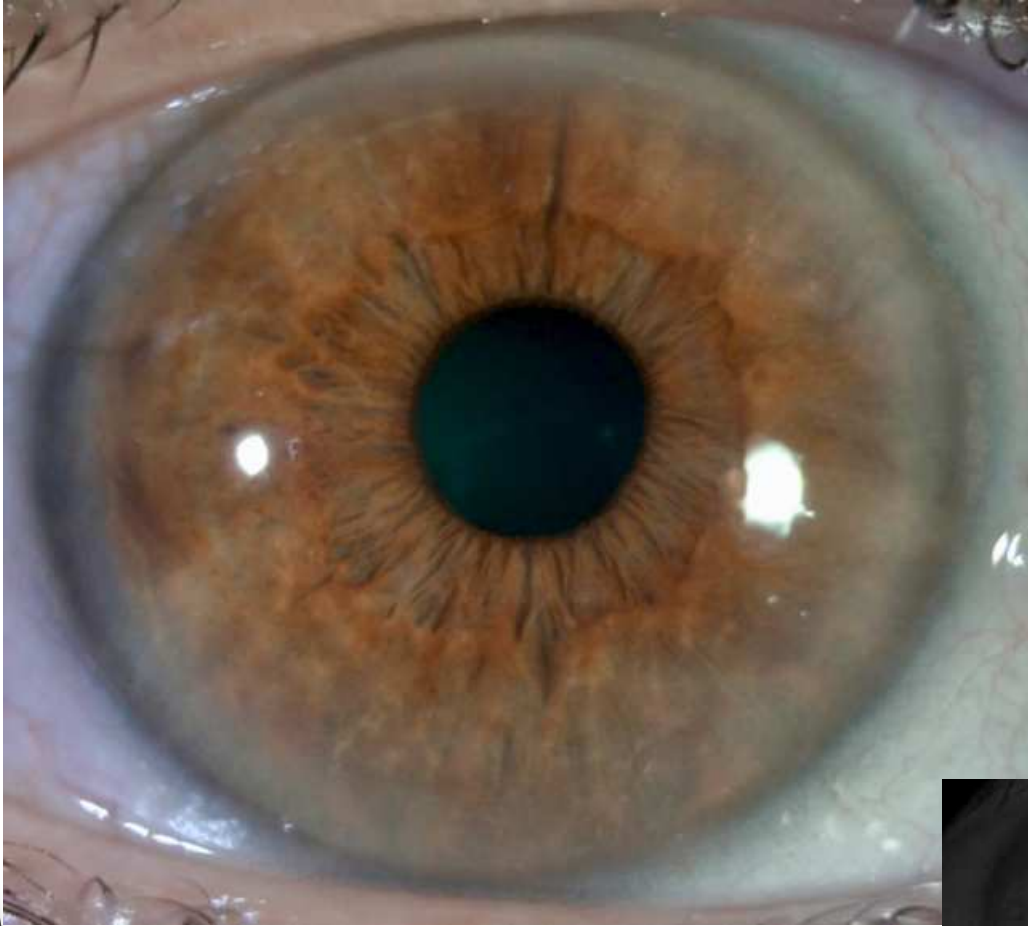
- F.G., woman 55 aa
- BCVA 6/10
- Symptoms +++
- Kmax: 53.1 D; Astig: 8.4 D





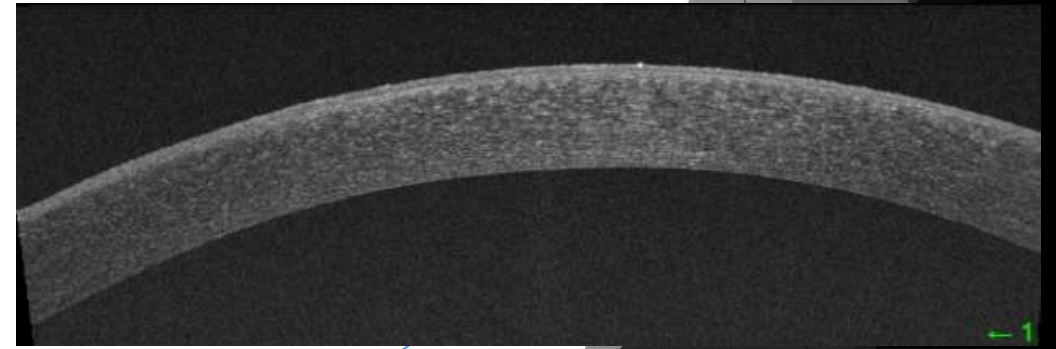
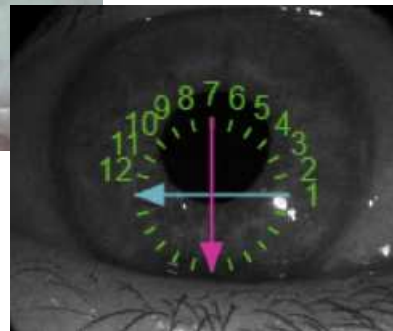
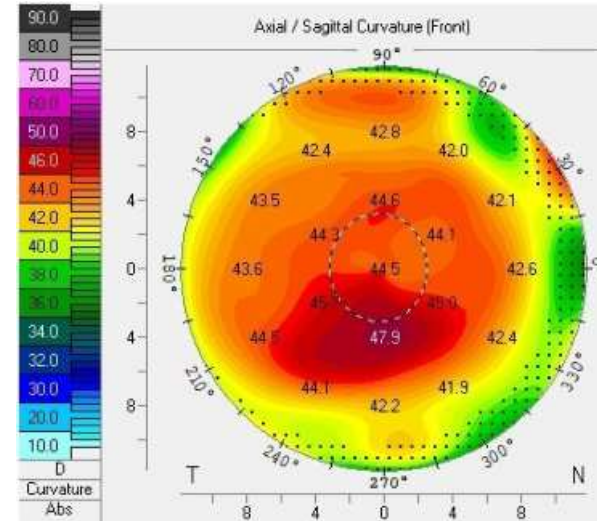
CASE 1

CASE 1

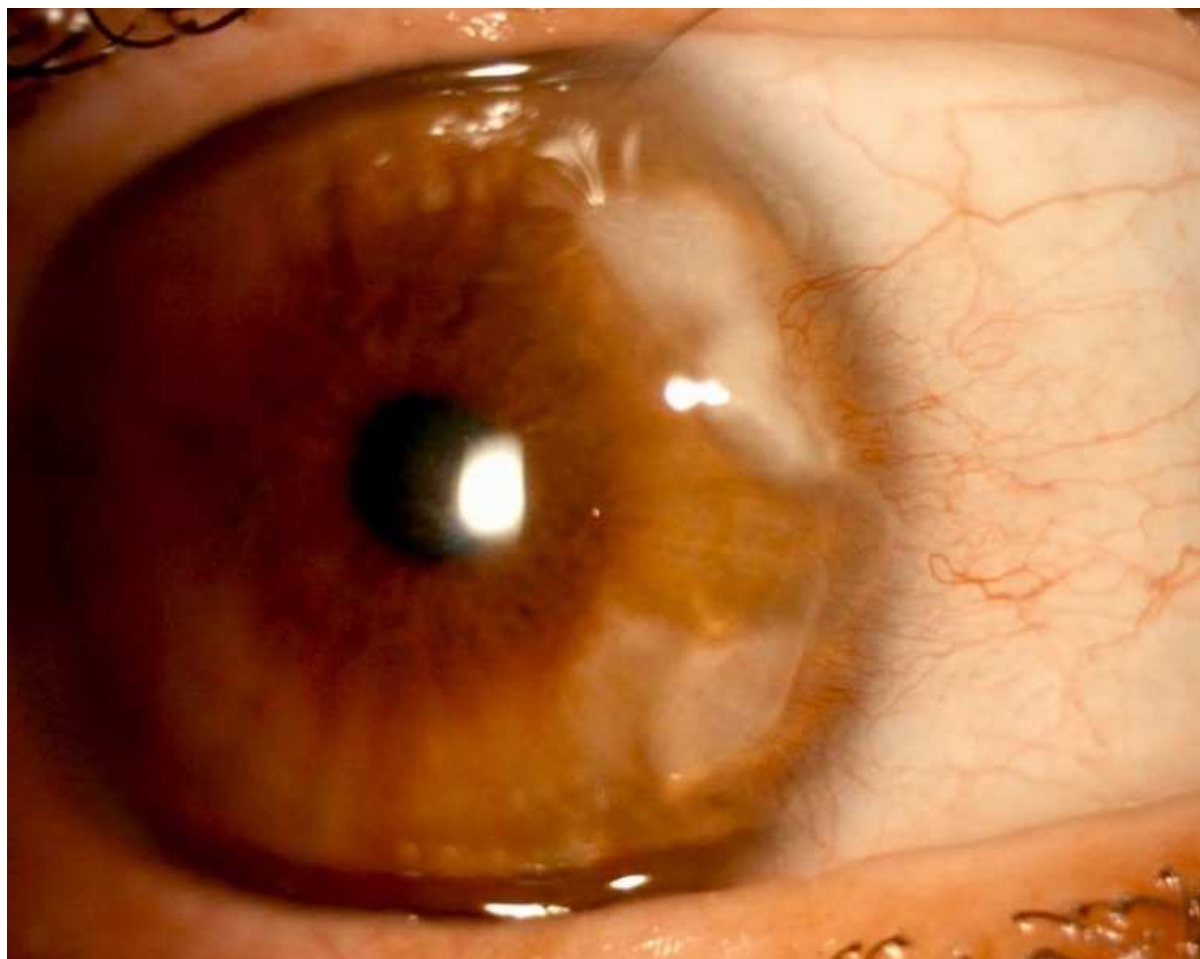


POST-OP 1 week:

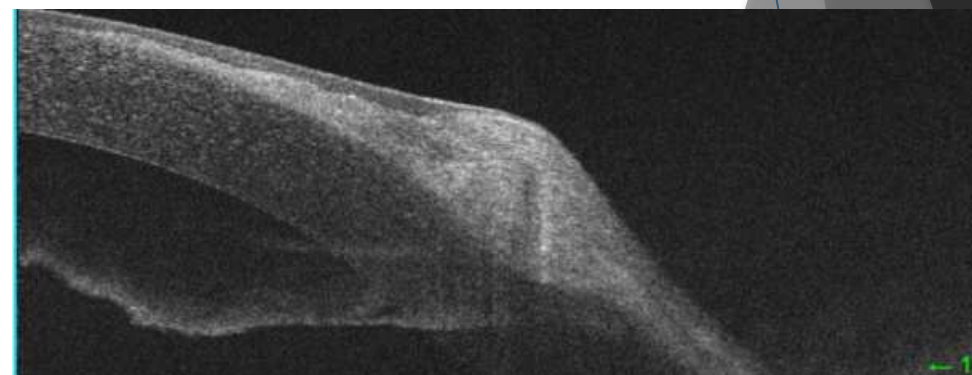
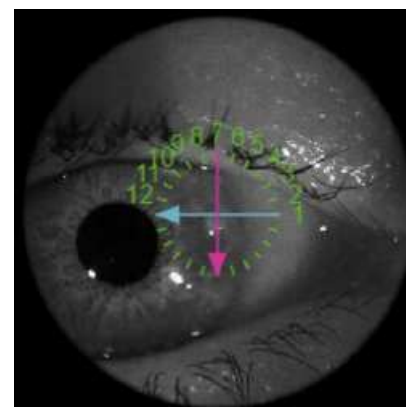
- BCVA 10/10
- Improvement of sintomatology
- Kmax: 47.9 D; Astig: 1.7 D

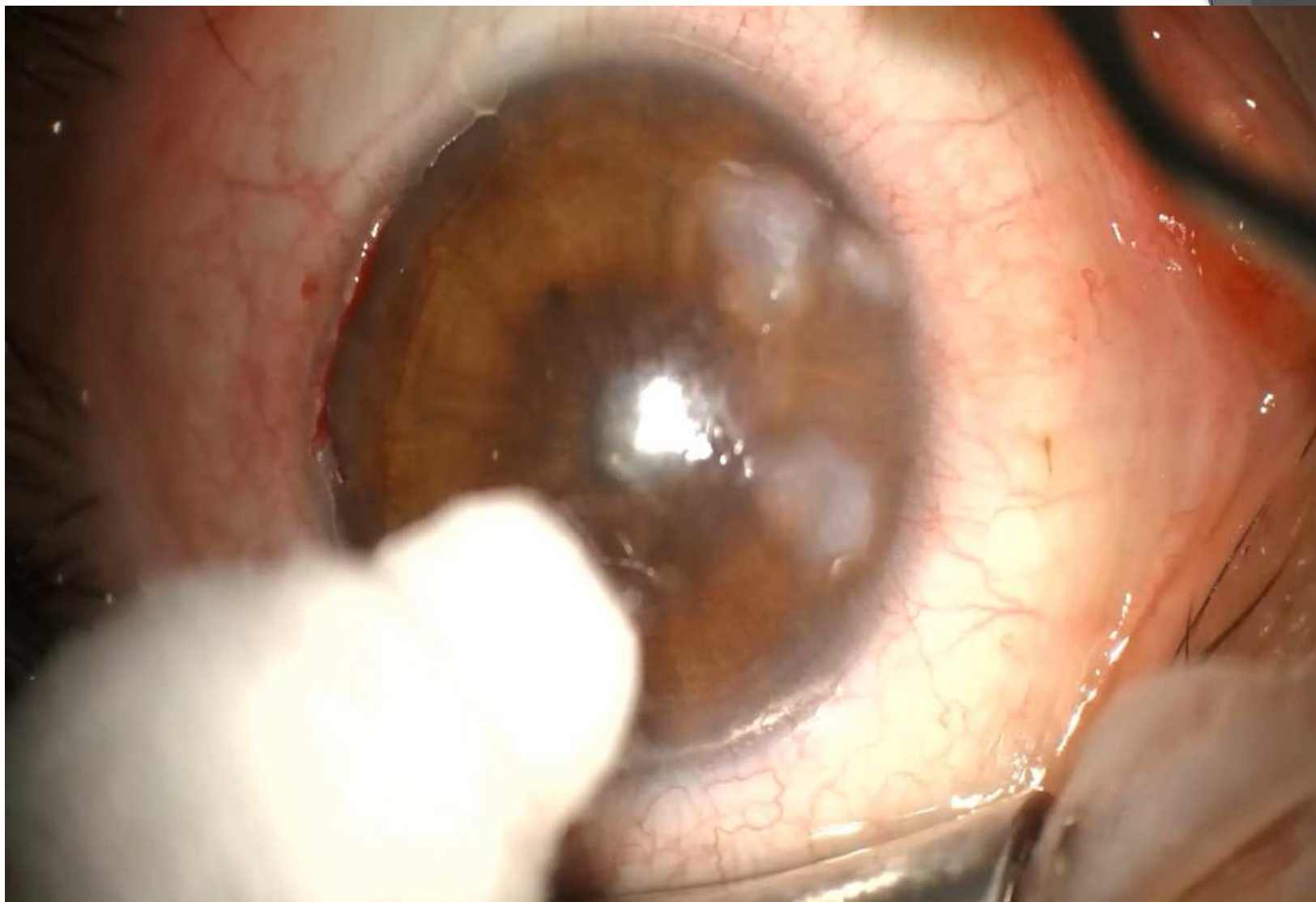


CASE 2



- N.C., woman 62 aa
- BCVA 8/10
- Symptoms +++
- Kmax: 49.2 D; Astig: 1.7 D

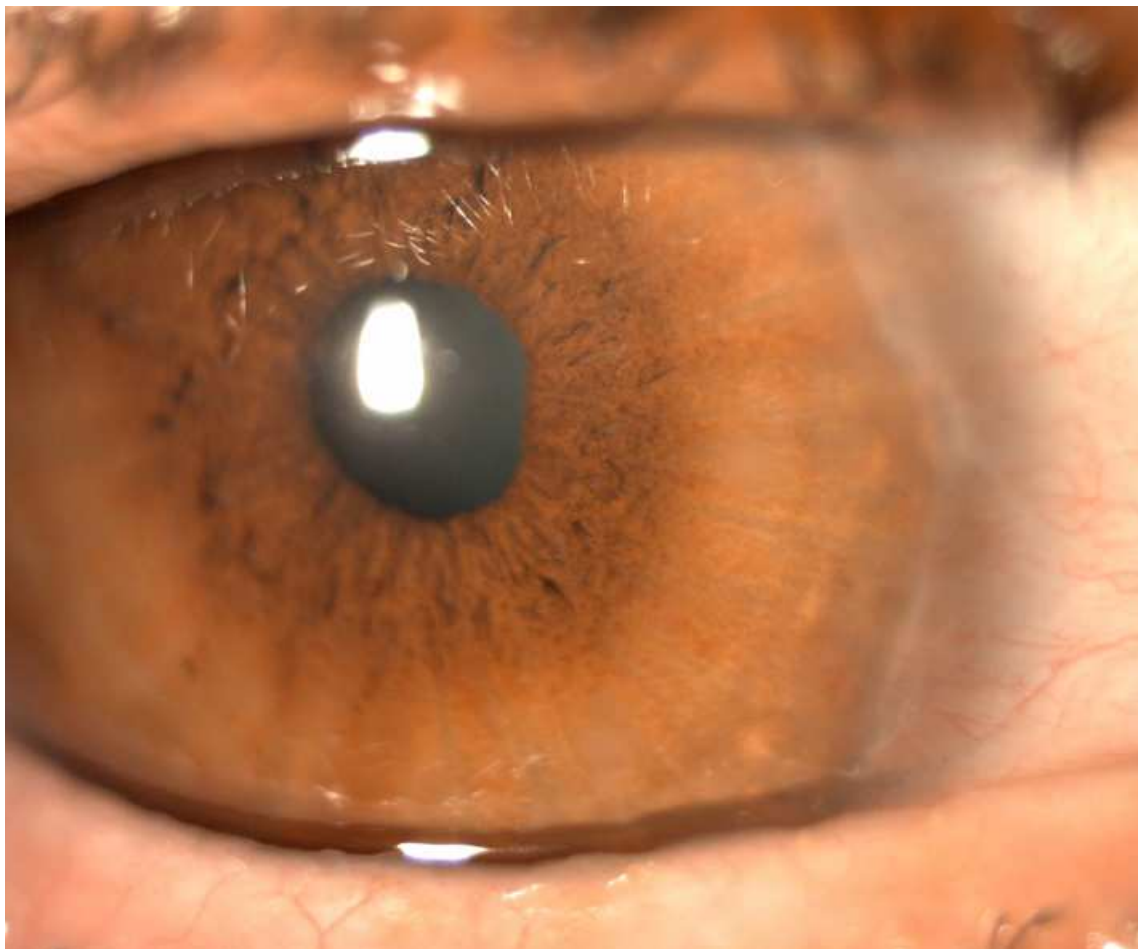



CASE 2

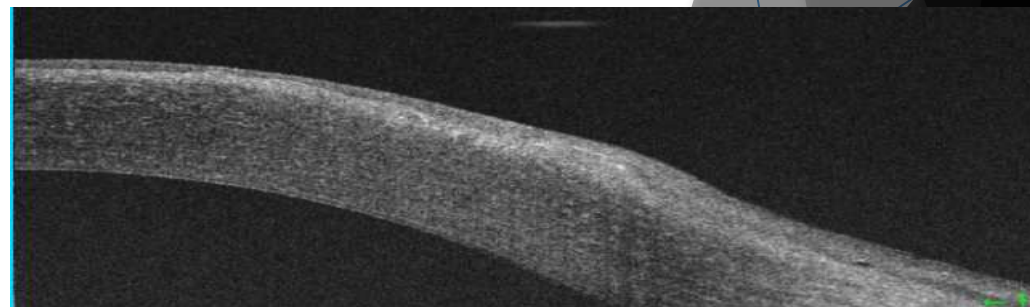
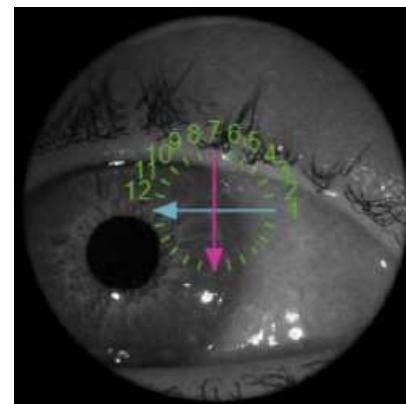
XLIX CONGRESSO REGIONALE S.O.SI • 10-12 APRILE 2025 • GIARDINI NAXOS (ME)

CASE 2



POST-OP 1 week:

- BCVA 10/10
- Improvement of sintomatology
- Kmax: 48.1 D; Astig: 0.6 D



TAKE HOME MESSAGES

- Management of SND depends on quality of life and AV of the patient.
- OCT plays a crucial role in choosing the best surgical option.
- The manual removal of nodules with an adequate cleavage plane is an absolutely valid technique as it is quick and guarantees better control of nodule resection with sparing of healthy tissue e adaptability in case of non-uniform lesions.
- PTK can be considered as a therapeutic complement to smooth the surface and remove mild residual opacities.

**THANKS
FOR YOUR
ATTENTION**



XLIX CONGRESSO REGIONALE S.O.SI • 10-12 APRILE 2025 • GIARDINI NAXOS (ME)